



The degenerative lumbar disc: not a disease, but still an important consideration for OMPT practice: a review of the history and science of discogenic instability

Brian T. Swanson & Douglas Creighton

To cite this article: Brian T. Swanson & Douglas Creighton (2020) The degenerative lumbar disc: not a disease, but still an important consideration for OMPT practice: a review of the history and science of discogenic instability, Journal of Manual & Manipulative Therapy, 28:4, 191-200, DOI: [10.1080/10669817.2020.1758520](https://doi.org/10.1080/10669817.2020.1758520)

To link to this article: <https://doi.org/10.1080/10669817.2020.1758520>



Published online: 04 May 2020.



Submit your article to this journal [↗](#)



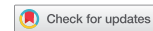Article views: 272




View related articles [↗](#)



View Crossmark data [↗](#)



The degenerative lumbar disc: not a disease, but still an important consideration for OMPT practice: a review of the history and science of discogenic instability

Brian T. Swanson ^a and Douglas Creighton^b

^aDepartment of Rehabilitation Sciences, University of Hartford, West Hartford, CT, USA; ^bSchool of Health Sciences, Oakland University, Rochester, MI, USA

ABSTRACT

Background: A recent AAOMPT position paper was published that opposed the use of the term ‘degenerative disc disease’ (DDD), in large part because it appears to be a common age-related finding. While common, there are significant physiologic and biomechanical changes that occur as a result of discogenic degeneration, which are relevant to consider during the practice of manual therapy.

Methods: A narrative review provides an overview of these considerations, including a historical perspective of discogenic instability, the role of the disc as a pain generator, the basic science of a combined biomechanical and physiologic cycle of degeneration and subsequent discogenic instability, the influence of rotation on the degenerative segment, the implications of these factors for manual therapy practice, and a perspective on an evidence-based treatment approach to patients with concurrent low back pain and discogenic degeneration.

Conclusions: As we consider the role of imaging findings such as DDD, we pose the following question: Do our manual interventions reflect the scientifically proven biomechanical aspects of DDD, or have we chosen to ignore the helpful science as we discard the harmful diagnostic label?

KEYWORDS

Degenerative disc; low back pain; review; biomechanics; physiology; manipulation; clinical reasoning; imaging

The American Academy of Orthopedic Manual Physical Therapists (AAOMPT) recently released a position statement and white paper, titled ‘AAOMPT Opposes The Use Of Degenerative Disc Disease’ [1] which states ‘... AAOMPT supports and encourages early physical therapy interventions with known effectiveness instead of high-risk procedures and medication, and strongly recommends that clinicians avoid using the diagnosis of degenerative disc disease’ [1]. This objection is based on several premises, namely that degenerative disc disease (DDD) is a common age-related observation and therefore not a disease, as well as overutilization of diagnostic imaging to direct treatment. The AAOMPT statement asserts ‘Both patients and providers use imaging to guide decisions related to intervention. However, emerging evidence highlights the potential negative impact that diagnostic labels used to describe imaging findings can have on patient outcomes.’ [1–3] We make no arguments regarding the need for thoughtful and judicious use of diagnostic labels; rather we suggest that imaging findings can, and should, inform and guide treatment decisions as one aspect of a larger clinical reasoning process. Disc degeneration is a common finding in adults with and without LBP less than 50 years of age [4], and a commentary by Lewis et al. cautions therapists not to base treatment on ‘normal’ age-related findings [5]. In the

selection of treatment technique, it has been suggested that ‘the choice of technique does not seem to matter as much as identifying an individual likely to respond’ [6]. However, more advanced disc degeneration is frequently observed at spinal levels where concordant symptoms are reproduced [7,8]. The International Society for the Study of the Lumbar Spine (ISSLS) has called DDD the most common cause of low back pain [9]. It has been postulated that the hallmarks of the degenerative process including tears of the annulus fibrosis, loss of disc height, alterations in loading and stability of the motion segment, and accompanying biochemical changes resulting in pain [9]. As we consider the role of imaging findings such as DDD, we pose the following question: Do our manual interventions reflect the scientifically proven biomechanical aspects of DDD, or have we chosen to ignore the helpful science as we discard the harmful diagnostic label? To assist in our understanding of matter, we begin with a historical perspective on disc degeneration, segmental instability and imaging.

1. Historical perspective

According to Wong and Transfeldt [10], instability secondary to disc degeneration is perhaps the most common

cause of low back pain. This was not a new observation, as Goldthwaith [11] (1911), Johnson [12] (1934), and Smith [13] (1934) wrote that lumbar vertebral instability was an important cause of severe low back pain. Knutsson [14] (1944), confirmed the presence of lumbar segmental instability using simple side bending, flexion and extension stress radiographs. He noted, long before the development of MRI, that segmental instability could be seen in lumbar segments *prior* to the development of advanced osteoarthritic changes and advanced disc space narrowing. In effect, Knutsson was one of the first researchers to describe the instability that results from early grade disc degeneration. Friberg [15] (1948), Friberg and Hirsch [16] (1949) and Harris and Macnab [17] (1954) all found segmental instability secondary to disc degeneration as confirmed by numerous spinal specimens removed at necropsy. These individuals consistently found instability to be associated with annular clefting and tears, including transverse or radial tears of the annulus fibrosus. In terms of excessive anterior and posterior vertebral translation secondary to disc degeneration, Schmorl and Junghanns [18] (1932) described discogenic instability using the term 'anterior pseudo-spondylolisthesis', which has been replaced by the term 'anterolisthesis'. Later, Schmorl and Junghanns [19] (1953) described 'posterior pseudo-spondylolisthesis', now commonly called 'retrolisthesis'.

Ian Macnab [20,21] (1971, 1977) was one of the early researchers who wrote and spoke about disc degeneration from a mechanical point of view. He eloquently defined disc degeneration as the 'breakdown in the mechanical integrity of the disc'. Macnab wrote that secondary to disc degeneration, spinal segmental motion becomes irregular and excessive, with a resultant 'loss of structural integrity' of the spinal motion segment. Accordingly, he wrote that any spinal segment with discogenic degeneration 'becomes vulnerable to trauma' and other forms of loading. Kirkaldy-Willis [22,23] (1982, 1978) wrote what is the generally accepted three-phase pathophysiological model of spinal degeneration. Commonly described as a 'cascade' of degenerative changes, the model consists of three sequential stages: 1) dysfunction, 2) instability and 3) stabilization. Were Macnab, Kirkaldy-Willis, and the other early researchers correct in their assertion that disc degeneration, including early grade disc degeneration, leads to segmental instability and the potential for both chronic and recurrent backache?

These early spine specialists and researchers laid the groundwork for other spinal researchers. Pfirrmann [24] (2001) helped to establish grades of disc degeneration using magnetic resonance imaging. Using the Pfirrmann scale and advanced imaging technology, more recent research has supported the work of early spinal scientists. Understanding the grades of disc degeneration, and their association with segmental instability, is important for the manual therapists of today who practice spinal manipulative therapy.

2. The disc as a pain generator

The disc itself is a potential source of pain, a concept Crock highlighted to the medical community during his 1985 address to the ISSLS [25]. Kuslich et al. [26] performed decompression surgery for herniated discs or spinal stenosis under local anesthesia in 193 consecutive patients. During surgery, the local segmental tissues were stimulated and patient response was recorded. They found muscle, fascia and vertebral bone to be largely insensitive (no pain reproduction), and the facet joint capsule was rarely provocative. The annulus, however, was provocative of lower back pain in over two-thirds of the patients. This finding can be explained through an understanding of the physiology of discogenic degeneration. Malinsky [27] and Yoshizawa [28] demonstrated the presence of encapsulated and unencapsulated pain receptors in the outer annulus, and Shinohara (1970) first identified nerve fibers in the inner portions of degenerative discs [29]. Pathological disc degeneration results in additional neural ingrowth into the outer two-thirds of the annulus, making the disc more pain sensitive [29]. This nociceptive neoinnervation is often found accompanied by annular tears [26–28]. In the healthy disc, a compact, stable network of collagen, as well as an environment rich in the proteoglycan aggrecan (which inhibits nerve growth *in vitro*) [30] prevent the growth of nerve fibers into the disc. Tears of the annulus disrupt the collagen complex, resulting in an inflammatory response and subsequently decreased proteoglycan content, including aggrecan, in the disc. Nerve growth factor (NGF), which promotes nerve ingrowth into the disc [31,32], is one of the inflammatory mediators present in this response, and upregulation of NGF following disc injury has been observed in both animal and human models [33]. The evidence clearly suggests that nerve growth into the disc is triggered by tears of the annulus, is promoted by increased levels of inflammatory mediators, and continues to progress due to the loss of proteoglycans (aggrecan) [34]. In the degenerated disc, uneven load distributions over the vertebral endplate lead to abnormal stress concentrations on the peripheral annulus [35–37]. As compressive load on the annulus increases, the annular fibers become progressively disorganized, accompanied by progressive cellular apoptosis and diminished aggrecan expression [38]. Continued abnormal stresses then prompt further inflammatory response [39], resulting in the stimulation of NGF mediated neoinnervation into the degenerated disc [34]. Repeated episodes of injury then lead to chronic inflammation and further degenerative changes [40].

3. The Disc as a source of instability

'Discogenic instability' is frequently observed in the absence of other specific disorders [41,42]. As we explore this concept, it is helpful to differentiate between range

of motion (ROM) and the neutral zone (NZ). ROM is limited by the passive osseoligamentous structures, while the NZ is inherently unstable; it is an area within which the spine has minimal internal resistance to movement, and therefore requires neuromuscular control [43,44]. The NZ, defined by the point in the movement at which resistance is first detected, has been shown to be a sensitive indicator of minor injury [45], and changes in NZ are believed to be closely related to clinical instability [43]. One method considered useful in expressing clinical instability is the NZ/ROM ratio, expressing the NZ (indicating laxity) as a percentage of the full ROM [46]. As intervertebral discs provide the majority of the intrinsic resistance to small spinal movements [47,48], and segmental instability results from discogenic degenerative changes [41,49,50], enlargement of the NZ is more indicative of instability than changes in ROM [44,51,52].

Multiple authors have investigated the role of discogenic degeneration on the development of neutral zone instability of the motion segment. Zhao et al. investigated the effects of disc dehydration resulting in 1 mm height loss (approximately 10% dehydration), followed by disruption of the endplate, changes noted to be typical of natural disc degeneration [53]. Following dehydration, NZ motion increased by 42–71%, respectively, in flexion and lateral bending, and this increased to 89–298% following compressive load induced endplate failure. Dehydration resulted in an increase of the ‘instability index’ (NZ/ROM) by approximately 13% for both motions, while endplate disruption resulted in an increase of 43% to 61%. Translatory motion increased by 27–36% following dehydration, which increased to 58–86% following endplate disruption [53]. Sengupta and Fan also identified increased NZ in spines with confirmed DDD, with concordant alterations in the axis of motion for rotational movements [54]. Axelsson and Karlsson demonstrated increased mobility, both vertical (compression/distraction) and translational, that persisted until the disc demonstrated 50% height loss [55]. Using kinetic MRI, Kong et al. observed progressively increasing translatory mobility across all Pfirrmann grades of degeneration, with a significantly higher prevalence in patients with Grade IV degenerative discs [56,57]. This finding has been further reproduced in post-operative discs; minimal removal of nuclear material has resulted in significant increases in mobility of the functional unit in all planes when compared with intact motion segments [55,58,59]. The mechanical effect has been further demonstrated by Rohlmann et al., who observed that in the presence of discogenic degeneration, during small moments the spinal load is transferred to the annular ground substance, while the facet joints and most ligaments are essentially unloaded [36].

The current research demonstrates the unquestionable role of discogenic degeneration in the development of frank and subtle instability of the lumbar motion segment. Discogenic degeneration leads to

a loss of height of the motion segment, with resultant buckling of the longitudinal ligaments; the ligaments require greater pre-tensioning stresses to serve in a stabilizing function [36], with ligamentous tension occurring much later than in the healthy segment [36]. Fujiwara et al. [60] examined 110 motion segments from 44 spines (average age 69 years), performing biomechanical and imaging studies on cadaveric spinal motion segments. They found disc degeneration to be associated with changes in spinal motion; lateral bending and rotation both increased with Grade I, II and III disc degeneration, and did not decrease until Grade V disc degeneration was achieved. Tanaka et al. [61] examined 114 lumbar motion segments from T12 – L5 taken from 47 fresh cadaver spines (average age 68 years), and demonstrated greater flexion, extension, and rotation ROM with disc degeneration up to grade III–IV, which they observed to be concurrent with tears of the annulus fibrosus. Muriuki et al. [62] observed that females demonstrated about one degree larger range of motion in all rotational modes following discogenic degeneration. Kettler et al. assessed an in-vitro database, and demonstrated that in the presence of DDD, stability to bending increased, while axial rotational stability decreased with a concurrent increase in neutral zone motion [63], findings that have been further reported by van Rijsbergen et al. [64]. Lao et al., in an in vivo MRI study, demonstrated the progression from normal disc, then progressive instability, with ankylosis ultimately occurring at Pfirrmann grade V [65], further confirming the early work of Kirkaldy-Willis [22,23].

4. Axial rotation as a source of annular stress

Previous work has demonstrated that forced rotation beyond 3° may produce structural damage, i.e. circumferential annular tears [66]. While an absolute tolerance of 12° torsional stress has been demonstrated before absolute failure occurs, damage is observed to occur at 3° [35]. In motion segments with discogenic degeneration, Mimura et al. [46] observed axial rotation per segment of up to 4.0°, and Rohlmann et al. [36] predicted up to 6.1°. Acaroglu et al. demonstrated that, during axial rotation, the largest strain occurs in the posterolateral aspect of the disc, in the direction of rotation, while flexion and contralateral lateral bending also increased strain and may place the disc at risk of injury [67]. Annular strain is an important consideration, as Gordon et al. demonstrated that the annulus fibrosus is the primary location of pathologic change in a reliable model of disc rupture using physiologically reasonable stress, and incorporating slight flexion (7°) and rotation of <3° [68].

The zygapophyseal joints provide a protective effect to the disc, orientated to limit total axial rotation to <3° under normal conditions [35]. Stress to the annulus fibrosus is increased if axial rotation occurs in combination with flexion [35,66]. Flexion results in increased

annular strain via a pre-load of the posterior annulus fibrosus; as a result less axial rotation is required to maximally strain collagen fibers [35,66]. In flexion, the facet joints afford less resistance to axial rotation, resulting in maximal annular stress, while the posterior elements provide less protective resistance [35,69]. Jelec et al. stated eloquently '*Axial rotation of the lower lumbar spine is undoubtedly associated with higher strain in disc annulus, and enhanced range of secondary rotational movements may be even more significant for the progression of annular degeneration*' [70].

5. Considerations for discogenic stresses during manual therapy

In a porcine model with a healthy motion segment, a 500 N force applied at the L4 transverse process resulted in $3.2 \pm 1.7^\circ$ rotation, while an identical force applied at the facet joint resulted in only 1.9° of rotation [71]. It was noted that significantly greater loads were experienced by intact specimens in response to greater force magnitudes during manipulation, and it is also apparent that longer levers result in significant increases in rotation at the motion segment. To put this in context, normal forces delivered during lumbar manipulation have been reported, ranging from 400 to 1400 N [72].

Wang et al. (2008) demonstrated progressive posterolateral loads with greater degrees of flexion during rotatory manipulations of the lumbar spine [73]. Wang et al. [74] (2018) investigated intradiscal pressures (IDP) comparing manipulations to mobilizations. They demonstrated that 'maximal IDP on the rotating side was greater than the contralateral side during simulated spinal mobilization and manipulation', while the rate of IDP development, with an increase of 33–58%, was significantly faster during manipulation. They conclude that 'thrust manipulation may have more instant impact to discs than mobilization' [74]. Discogenic degeneration has been shown to significantly increase nucleus pulposus stiffness, resulting in unequal stress distributions within the disc, and higher force concentrations in the annulus [37,75]. Li et al. have demonstrated that the annular forces, annular stress and IDP are all higher in mildly and moderately degenerated discs than healthy segments during rotational manipulation [76]. Fujita et al. reported that degenerated discs demonstrated yield and ultimate stress up to 30% lower when compared with normal discs, with the observed alterations in the mechanical properties beginning in the early stages of disc degeneration [77].

Degeneration of the disc also results in alteration of the axis of rotation; with mild to moderate degenerative changes, the axis of rotation migrates posteriorly, closer to the apophyseal joints [53]. Zhou et al. demonstrated that, in the presence of severe degeneration, the superior vertebrae can pivot about the inferior apophyseal joints [53]. During manipulative forces

applied into axial rotation, this is demonstrated via increased forces in the contralateral facet joints, which become more prevalent with higher grades of disc degeneration. Mechanically, this shift of the axis of rotation to the contralateral facet results in increased stress on the posterolateral annulus in the manipulative direction of rotation.

6. Implications for practice

If forced rotation stresses the annulus, flexion minimizes the ability of the facet to limit rotation, discogenic degeneration allows greater overall rotation to occur, and the annulus has a lower ability to tolerate rotational stresses with DDD, why do we apply rotational manipulations in this population? Taken as a whole, this literature suggests caution in the application of rotatory lumbar manipulation in the presence of early grade disc degeneration. Many alternatives exist for our consideration. Oscillatory spinal manual therapy interventions [78], applied prior to tissue resistance, will likely benefit painful motion segments with early grade disc degeneration. Manual interventions, particularly oscillatory techniques [79,80], are often applied for the purposes of sensory modulation [6,81] and likely would not further compromise the structural integrity of a motion segment with a degenerated disc. Distraction and stabilization have been suggested as creating suitable conditions for disc rehydration and, therefore, potential regeneration [82,83]. Accordingly, traction-based manual interventions [84,85] applied to degenerated hypermobile-unstable segments, and delivered with the intent of decompressing painful segments in patients who demonstrate discogenic hypermobility-instability both with and without radiculitis [10] is another example of spinal manual intervention that respects the existing scientific work on disc degeneration [41,49,53,54,60,63,65]. Studies have demonstrated that manipulations utilizing a distractive force may be effective in individuals with degenerative spinal conditions [86], generate lower forces within the disc, including application in both flexion and extension, and may be safer alternatives to rotatory manipulation [87–92]. In cases of symptomatic discogenic hypermobility, perhaps we should mobilize with the lumbar segments in mid-position with a decompressive traction-like load [85].

While decreased diffusion of water and loss of PG content are hallmarks of DDD, it has been suggested that fluid exchange is integral to maintaining disc nutrition [93], and tissue swelling is an important consideration for strategies aimed at restoring normal mechanical behavior of the disc [94]. Mobilizations such as P-A glides have been reported to result in pain relief and improved motion in individuals with low back pain [78,95,96] while also improving disc hydration [97–99]. However, in the presence of discogenic degeneration, Gr III/IV P-A mobilizations may generate increased neutral zone shear [100–102]. Careful testing and clinical reasoning are

required in application of this treatment. Prone extension exercises also improve hydration [97,98]; however, the expected nuclear movements are based on a healthy lumbar disc model, where the nucleus is displaced anteriorly by extension and posteriorly by flexion [103,104]. While discs with grade I degeneration appear to behave as expected [105], changes in intradiscal pressure and position are not predictable in discs with significant degeneration [103,105–107] and degenerative discs have been reported to bulge posteriorly during extension motions [104,105,108]. As disc degeneration progresses, focal areas of compressive stress and shearing within the annulus rise by up to 75% in flexion and 108% during extension [37]. The application of gentle tension forces to the annulus, such as those generated during mid-range traction interventions, have been shown to improve disc hydration [109–113], induce extracellular matrix gene expression [114] and improve disc nutrition via fluid movement [115], all of which may inhibit further degenerative changes in the annulus. As disc dehydration has been shown to increase instability [53], and improved hydration has been reported to reduce spinal flexibility [111] and maintain normal mechanical stiffness [94], mid-range mobilization and traction interventions would appear to be beneficial in the population with discogenic instability without undesirable mechanical stresses.

The resulting expansion of the neutral zone in individuals with discogenic degeneration requires a greater contribution from the local musculature [43]. The multifidus has been shown to create up to two-thirds of the stability of the segment in the neutral zone, and is perhaps the muscle most well suited for direct stabilization of the segment in mid-range [116–121]. We have known since the 1990's that first time backache causes immediate changes in the multifidus, and that spontaneous recovery of the multifidus does not happen unless we strengthen it [122]. The degenerative changes in the multifidus appear to be an increase in adipose/connective tissue; Hodges et al. demonstrated a meaningful association of multifidus adiposity following disc injury in a case-control model [123]. Despite reports that aging may account for some of the variance observed in fatty infiltration of the multifidus, greater levels of fatty infiltration are observed in individuals with lumbar degenerative disease compared to healthy individuals, regardless of age [124]. Rapid onset of atrophy and fatty infiltration has been observed in experimentally induced discogenic degeneration, and a relationship between disc degeneration and fatty infiltration of the multifidus has been observed in the presence of reduced IVD height in both an animal model [125,126] and in vivo [127]. This loss of function is of obvious clinical importance; during kinetic MRI, excessive angular motion was significantly associated with fatty infiltration of the paraspinal musculature [57].

In motion segments with discogenic degeneration, normal multifidus tensile and loading forces may not

occur as a result of reductions in muscular activity [128–130] and/or modified movement patterns [131]. The resulting alterations of mechanical input to the muscle (mechanotransduction), and subsequent changes in genetic and molecular signaling [132,133], are at least partly responsible for the observed functional and structural changes in the multifidus—alterations in mechanotransduction have been shown to mediate changes in muscle fiber composition [134–136]. Specific exercise may result in more normal mechanotransduction to the multifidus, triggering molecular mechanisms and subsequent structural improvements [136,137]. Evidence supports exercise as a means to induce change in multifidus function [122,138]; stabilization (multifidus specific) exercises demonstrate a more favorable outcome when compared to generalized lumbar ROM exercises and physician advice [139]. Exercises addressing the local stabilizers would appear to be a logical treatment in the treatment of degenerative instability.

7 Conclusions/recommendations

How do we assist patients with lower backache and segmental instability secondary to disc degeneration? We believe manual traction and oscillatory distraction mobilizations, which can be applied in several different fashions, can decompress pain-sensitive segments and will not foster further segmental instability. It is our contention that this traction-based manual intervention should be performed with lumbar segments in mid-position without the addition of side bending or rotation. Pain science studies have consistently found vibratory and oscillatory motion to be effective in reducing pain [79,80,140], and we believe this applies to lumbar discogenic pain as well. In addition, low-load, supported, mid-position flexor and extensor muscle (stabilization) training may be of benefit in terms of enhancing dynamic/muscular-based segmental stability [122,139,141,142].

Considering the frequency of discogenic degeneration observed in the asymptomatic population, with rates ranging from 52% at age 30 to 88% at age 60 [4], we believe the resulting instability and increased rotational mobility in affected lumbar segments may be underappreciated in the clinical practice of spinal manual therapy. Historical and contemporary spinal science has proven that early grade disc degeneration is associated with segmental instability. We believe that oscillatory traction-based manual interventions applied in conjunction with stabilization exercise, neuromuscular reeducation and other helpful therapeutic advice is consistent with the 'early physical therapy interventions with known effectiveness' that AAOMPT suggests [1].

As the underlying problem is most likely an issue of instability, rather than hypomobility, the use of manual interventions which protect unstable motion segments,

enhance disc rehydration [109,110,112,113] and nutrition [115], facilitate neuromodulation [79,80], and reduce muscular inhibition [143–145], followed by a thoughtful exercise program, represents a treatment approach for the patient with known discogenic degeneration that is supported by the historical and contemporary science. So, let's not discard or ignore the imaging findings; rather let's apply them in context with the research. Let us continue to be aware that most of our painful middle-aged patients, and many of our older spinal pain patients, haven't yet reached the stabilization phase of Kirkaldy-Willis's pathophysiological model and are, in fact, painful due to discogenic hypermobility-instability. This may then be, as Haldorsen asks us to consider in our treatments of LBP, 'the right treatment, to the right patient, and the right time.' [146] It is a point of view that is critical to all who practice spinal manipulative therapy.

Key concepts:

- (1) Use of the term disease should be avoided, but discogenic degeneration and discogenic instability have meaningful clinical implications.
- (2) The basic science supports a combined biomechanical and physiologic cycle of degeneration, driven by a combination of excessive mechanical stresses and biochemically mediated tissue breakdown.
- (3) Rotational instability is an early, significant consequence of discogenic degeneration.
- (4) Forceful rotatory treatments may cause further tissue damage, potentially leading to additional loss of structural integrity of the disc.
- (5) Based on the current science, mid-position traction techniques for hydration and neuromodulation purposes, paired with multifidus-specific stabilization exercises, may be the most appropriate OMPT interventions.

Disclosure statement

No potential conflict of interest was reported by the authors.

Notes on contributors

Brian T. Swanson has been recognized as a board-certified orthopaedic clinical specialist, a Fellow of the American Academy of Orthopaedic Manual Physical Therapy, and is certified in multiple manual therapy systems. He has been in clinical practice since 1996, a full-time faculty member since 2014, and involved with post-professional residency education since 2016. He is currently an Assistant Professor in the Department of Rehabilitation Sciences at the University of Hartford, where his teaching responsibilities include the Examination and Intervention of Musculoskeletal Pathologies (spine and extremity) and Scientific Inquiry courses. Dr. Swanson has published multiple papers related to manual therapy of the spine and shoulder girdle.

Douglas Creighton holds certifications in two different systems of manual therapy. He has been in clinical practice since 1985, and a full-time faculty member at Oakland University since 1998. His teaching responsibilities are spread across both the entry-level and post-profession programs. He teaches across both the basic science and orthopedic curriculum including Musculoskeletal Imaging, and Arthrology, a cadaver-based anatomy course, which looks at joint surface shape and orientation, capsular anatomy, and in-depth exploration of degenerative changes including chondral defects, arthritic and spondylotic hypertrophy, and degenerative disc narrowing. He is also responsible for an orthopedic Examination and Therapeutic Exercise course. His post-professional teaching occurs in Oakland University's orthopedic manual physical therapy program where he and John Krauss provide both didactic and residency-based education for their students. Dr. Creighton has developed an orthopedic examination textbook and a therapeutic exercise textbook. He has published work related to radiological confirmation of lumbar foraminal opening with therapeutic positioning, diagnostic ultrasound imaging of vertebral artery blood flow during upper and lower cervical manual therapy interventions, and various levels of research which has looked at both manual and exercise intervention for orthopedic pain and motion impairments in patients with orthopedic degenerative spinal and extremity conditions.

ORCID

Brian T. Swanson  <http://orcid.org/0000-0002-7146-4537>

References

- [1] Emerson A, Naze G, Mabry LM, et al. AAOMPT opposes the use of the term degenerative disc disease. Accessed 2020 Apr 11. Available at: https://aaompt.org/Main/Public_Resources/Position_Statements/Main/About_Us/Position_Statements.aspx?hkey=03f5a333-f28d-4715-b355-cb25fa9bac2c.
- [2] Darlow B, Dean S, Perry M, et al. Easy to harm, hard to heal: patient views about the back. *Spine (Phila PA 1976)*. 2015;40(11):842–850.
- [3] Lin IB, O'Sullivan PB, Coffin JA, et al. Disabling chronic low back pain as an iatrogenic disorder: a qualitative study in Aboriginal Australians. *BMJ Open*. 2013;3(4):e002654.
- [4] Brinjikji W, Diehn F, Jarvik J, et al. MRI findings of disc degeneration are more prevalent in adults with low back pain than in asymptomatic controls: a systematic review and meta-analysis. *AJNR Am J Neuroradiol*. 2015;36(12):2394–2399.
- [5] Lewis JS, Cook CE, Hoffmann TC, et al. The elephant in the room: too much medicine in musculoskeletal practice. *J Orthop Sports Phys Ther*. 2020;50(1):1–4.
- [6] Bialosky JE, Bishop MD, Price DD, et al. The mechanisms of manual therapy in the treatment of musculoskeletal pain: a comprehensive model. *Man Ther*. 2009;14(5):531–538.
- [7] Jensen RK, Kent P, Jensen TS, et al. The association between subgroups of MRI findings identified with latent class analysis and low back pain in 40-year-old Danes. *BMC Musculoskelet Disord*. 2018;19(1):62.
- [8] Weishaupt D, Zanetti M, Hodler J, et al. Painful lumbar disk derangement: relevance of endplate abnormalities at MR imaging. *Radiology*. 2001;218(2):420–427.

- [9] Venkatesh PKMC, Bolger C. Lumbar spine online textbook. Section 12, chapter 5: motion preservation for lumbar disc degeneration. International Society for the Study of the Lumbar Spine. Towson, MD: Data Trace Publishing; 2019. <http://www.wheelsonline.com/ISSLS/section-12-chapter-5-motion-preservation-for-lumbar-disc-degeneration/>.
- [10] Wong D, Transfeldt E. Macnab's Backache. 4th ed. Baltimore/London: Lippincott Williams & Wilkins; 2007.
- [11] Goldthwait JE. The lumbo-sacral articulation; an explanation of many cases of "Lumbago," "Sciatica" and Paraplegia. *Boston Med Surg J.* 1911;164(11):365-372.
- [12] Johnson JRRW. Posterior luxations of the lumbosacral joint. *J Bone Joint Surg.* 1934;16(4):867-876.
- [13] Smith AD. Posterior displacement of the fifth lumbar vertebra. *J Bone Joint Surg.* 1934;16(4):877-888.
- [14] Knutsson F. The instability associated with disk degeneration in the lumbar spine. *Acta Radiol.* 1944;25(5-6):593-609.
- [15] Friberg S. Anatomical studies on lumbar disc degeneration. *Acta Orthop Scand.* 1948;17(1-4):224-230.
- [16] Friberg S, Hirsch C. Anatomical and clinical studies on lumbar disc degeneration. *Acta Orthop Scand.* 1949;19(2):222-242.
- [17] Harris R, Macnab I. Structural changes in the lumbar intervertebral discs: their relationship to low back pain and sciatica. *J Bone Joint Surg Br.* 1954;36-B(2):304-322.
- [18] Schmorl G, Junghanns H. Die Gesunde und Kranke Wirbels, Rontgenbild. Leipzig: Georg Thieme Verlag; 1932.
- [19] Schmorl G, Junghanns H. Die Gesunde und die Kranke Wirbels Klinik. Stuttgart: Georg Thieme Verlag; 1953.
- [20] Macnab I. The traction spur. An indicator of segmental instability. *J Bone Joint Surg Am.* 1971;53(4):663-670.
- [21] Macnab I. Backache. Baltimore/London: Williams & Wilkins; 1977.
- [22] Kirkaldy-Willis W, Farfan H. Instability of the lumbar spine. *Clin Orthop Relat Res.* 1982;165:110-123.
- [23] Kirkaldy-Willis W, Wedge J, Yong-Hing K, et al. Pathology and pathogenesis of lumbar spondylosis and stenosis. *Spine (Phila PA 1976).* 1978;3(4):319-328.
- [24] Pfirrmann CW, Metzendorf A, Zanetti M, et al. Magnetic resonance classification of lumbar intervertebral disc degeneration. *Spine (Phila PA 1976).* 2001;26(17):1873-1878.
- [25] Crock HV. The presidential address: ISSLS. *Spine (Phila PA 1976).* 1986;11(6):650-653.
- [26] Kuslich S, Ulstrom C, Michael C. The tissue origin of low back pain and sciatica: a report of pain response to tissue stimulation during operations on the lumbar spine using local anesthesia. *Orthop Clin North Am.* 1991;22(2):181.
- [27] Malinsky J. The ontogenetic development of nerve terminations in the intervertebral discs of man (histology of intervertebral discs, 11th communication). *Cells Tissues Organs.* 1959;38(1-2):96-113.
- [28] Yoshizawa H, O'Brien JP, Thomas Smith W, et al. The neuropathology of intervertebral discs removed for low-back pain. *J Pathol.* 1980;132(2):95-104.
- [29] Shinohara H. A study on lumbar disc lesion significance of histology of free nerve endings in lumbar disc. *J Jpn Orthop Assoc.* 1970;44:553-570.
- [30] Johnson WE, Caterson B, Eisenstein SM, et al. Human intervertebral disc aggrecan inhibits nerve growth in vitro. *Arthritis Rheum.* 2002;46(10):2658-2664.
- [31] Aoki Y, Takahashi Y, Ohtori S, et al. Distribution and immunocytochemical characterization of dorsal root ganglion neurons innervating the lumbar intervertebral disc in rats: a review. *Life Sci.* 2004;74(21):2627-2642.
- [32] Yamauchi K, Inoue G, Koshi T, et al. Nerve growth factor of cultured medium extracted from human degenerative nucleus pulposus promotes sensory nerve growth and induces substance p in vitro. *Spine (Phila PA 1976).* 2009;34(21):2263-2269.
- [33] Miyagi M, Ishikawa T, Orita S, et al. Disk injury in rats produces persistent increases in pain-related neuropeptides in dorsal root ganglia and spinal cord glia but only transient increases in inflammatory mediators: pathomechanism of chronic diskogenic low back pain. *Spine (Phila PA 1976).* 2011;36(26):2260-2266.
- [34] Ohtori SAY, Orita S. Pain generators and pathways of degenerative disc disease. Lumbar Spine online textbook. International Society for the Study of the Lumbar Spine. Towson, MD: Data Trace Publishing; 2019
- [35] Bogduk N. The lumbar disc and low back pain. *Neurosurg Clin N Am.* 1991;2(4):791-806.
- [36] Rohlmann A, Zander T, Schmidt H, et al. Analysis of the influence of disc degeneration on the mechanical behaviour of a lumbar motion segment using the finite element method. *J Biomech.* 2006;39(13):2484-2490.
- [37] Stefanakis M, Luo J, Pollintine P, et al. ISSLS prize winner: mechanical influences in progressive intervertebral disc degeneration. *Spine (Phila PA 1976).* 2014;39(17):1365-1372.
- [38] Lotz JC, Colliou OK, Chin JR, et al. Volvo award winner in biomechanical studies. *Spine (Phila PA 1976).* 1998;23(23):2493-2506.
- [39] Miyagi M, Ishikawa T, Kamoda H, et al. ISSLS prize winner: disc dynamic compression in rats produces long-lasting increases in inflammatory mediators in discs and induces long-lasting nerve injury and regeneration of the afferent fibers innervating discs: a pathomechanism for chronic discogenic low back pain. *Spine (Phila PA 1976).* 2012;37(21):1810-1818.
- [40] Ulrich JA, Liebenberg EC, Thuillier DU, et al. ISSLS prize winner: repeated disc injury causes persistent inflammation. *Spine (Phila PA 1976).* 2007;32(25):2812-2819.
- [41] Sato H, Kikuchi S. The natural history of radiographic instability of the lumbar spine. *Spine (Phila PA 1976).* 1993;18(Supplement):2075-2079.
- [42] Iguchi T, Kanemura A, Kasahara K, et al. Age distribution of three radiologic factors for lumbar instability: probable aging process of the instability with disc degeneration. *Spine (Phila PA 1976).* 2003;28(23):2628-2633.
- [43] Panjabi MM. The stabilizing system of the spine. Part II. Neutral zone and instability hypothesis. *J Spinal Disord.* 1992;5(4):390.
- [44] Adams MA. editor. Biomechanics of the intervertebral disc, vertebra and ligaments. Szpalski M GR, Pope MH, eds. Lumbar Segmental Instability. Philadelphia: Lippincott Williams & Wilkins; 1999.
- [45] Oxland TR, Panjabi MM. The onset and progression of spinal injury: a demonstration of neutral zone sensitivity. *J Biomech.* 1992;25(10):1165-1172.
- [46] Mimura M, Panjabi M, Oxland T, et al. Disc degeneration affects the multidirectional flexibility of the lumbar spine. *Spine (Phila PA 1976).* 1994;19(12):1371-1380.
- [47] Adams M, Dolan P, Hutton W. The lumbar spine in backward bending. *Spine (Phila PA 1976).* 1988;13(9):1019-1026.
- [48] Adams M, Hutton W, Stott J. The resistance to flexion of the lumbar intervertebral joint. *Spine (Phila PA 1976).* 1980;5(3):245-253.

- [49] Brown MD, Holmes DC, Heiner AD. Measurement of cadaver lumbar spine motion segment stiffness. *Spine (Phila PA 1976)*. 2002;27(9):918–922.
- [50] Weiler P, King J, Gertzbein S. Analysis of sagittal plane instability of the lumbar spine in Vivo. *Spine (Phila PA 1976)*. 1990;15(12):1300–1306.
- [51] Pope MHOM, Okawa A, ed. Biomechanical measurements. Szpalski M GR, Pope MH, ed. *Lumbar Segmental Instability*. Philadelphia: Lippincott Williams & Wilkins; 1999.
- [52] Pope MH, Panjabi M. Biomechanical definitions of spinal instability. *Spine (Phila PA 1976)*. 1985;10(3):255–256.
- [53] Zhao F, Pollintine P, Hole BD, et al. Discogenic origins of spinal instability. *Spine (Phila PA 1976)*. 2005;30(23):2621–2630.
- [54] Sengupta DK, Fan H. The basis of mechanical instability in degenerative disc disease: a cadaveric study of abnormal motion versus load distribution. *Spine (Phila PA 1976)*. 2014;39(13):1032–1043.
- [55] Axelsson P, Karlsson BS. Intervertebral mobility in the progressive degenerative process. A radiostereometric analysis. *Eur Spine J*. 2004;13(6):567–572.
- [56] Kong MH, Morishita Y, He W, et al. Lumbar segmental mobility according to the grade of the disc, the facet joint, the muscle, and the ligament pathology by using kinetic magnetic resonance imaging. *Spine (Phila PA 1976)*. 2009;34(23):2537–2544.
- [57] Kong MH, Hymanson HJ, Song KY, et al. Kinetic magnetic resonance imaging analysis of abnormal segmental motion of the functional spine unit. *J Neurosurg Spine*. 2009;10(4):357–365.
- [58] Kuroki H, Goel VK, Holekamp SA, et al. Contributions of flexion–extension cyclic loads to the lumbar spinal segment stability following different discectomy procedures. *Spine (Phila PA 1976)*. 2004;29(3):E39–E46.
- [59] Goel VK, Nishiyama K, Weinstein JN, et al. Mechanical properties of lumbar spinal motion segments as affected by partial disc removal. *Spine (Phila PA 1976)*. 1986;11(10):1008–1012.
- [60] Fujiwara A, Lim T-H, An HS, et al. The effect of disc degeneration and facet joint osteoarthritis on the segmental flexibility of the lumbar spine. *Spine (Phila PA 1976)*. 2000;25(23):3036–3044.
- [61] Tanaka N, An HS, Lim T-H, et al. The relationship between disc degeneration and flexibility of the lumbar spine. *Spine J*. 2001;1(1):47–56.
- [62] Muriuki MG, Havey RM, Voronov LI, et al. Effects of motion segment level, Pfirrmann intervertebral disc degeneration grade and gender on lumbar spine kinematics. *J Orthop Res*. 2016;34(8):1389–1398.
- [63] Kettler A, Rohlmann F, Ring C, et al. Do early stages of lumbar intervertebral disc degeneration really cause instability? Evaluation of an in vitro database. *Eur Spine J*. 2011;20(4):578–584.
- [64] van Rijsbergen MM, Barthelemy VMP, Vrancken ACT, et al. Moderately degenerated lumbar motion segments: are they truly unstable? *Biomech Model Mechanobiol*. 2017;16(2):537–547.
- [65] Lao L, Daubs MD, Scott TP, et al. Effect of disc degeneration on lumbar segmental mobility analyzed by kinetic magnetic resonance imaging. *Spine (Phila PA 1976)*. 2015;40(5):316–322.
- [66] Pearcy M. Inferred strains in the intervertebral discs during physiological movements. *Man Med*. 1990;5:68–71.
- [67] Acaroglu ER, Latridis JC, Setton LA, et al. Degeneration and aging affect the tensile behavior of human lumbar annulus fibrosus. *Spine (Phila PA 1976)*. 1995;20(24):2690–2701.
- [68] Gordon SJ, Yang KH, Mayer PJ, et al. Mechanism of disc rupture. A preliminary report. *Spine (Phila PA 1976)*. 1991;16(4):450–456.
- [69] Ahmed AM, Duncan NA, Burke DL. The effect of facet geometry on the axial torque–rotation response of lumbar motion segments. *Spine (Phila PA 1976)*. 1990;15(5):391–401.
- [70] Jelec V. Facet orientation and tropism: association with accelerated degeneration of stabilizing structures in lower lumbar spine. *Acta Clin Croat*. 2016;55(1):117–124.
- [71] Funabashi M, Nougrou F, Descarreaux M, et al. Influence of spinal manipulative therapy force magnitude and application site on spinal tissue loading: a biomechanical robotic serial dissection study in porcine motion segments. *J Manipulative Physiol Ther*. 2017;40(6):387–396.
- [72] Owens EF Jr, Hosek RS, Mullin L, et al. Thrust magnitudes, rates, and 3-dimensional directions delivered in simulated lumbar spine high-velocity, low-amplitude manipulation. *J Manipulative Physiol Ther*. 2017;40(6):411–419.
- [73] Wang G-L, Zhang M-C, Li Y-K, et al. Comparison of lumbar rotation manipulation in three lumbar flexion levels. *J Cervicodynia Lumbodynia*. 2008; 1.
- [74] Wang F, Zhang J, Feng W, et al. Comparison of human lumbar disc pressure characteristics during simulated spinal manipulation vs. spinal mobilization. *Mol Med Rep*. 2018;18(6):5709–5716.
- [75] Adams M, McNally D, Dolan P. ‘Stress’ distributions inside intervertebral discs. *J Bone Joint Jurg Br*. 1996;78-B(6):965–972.
- [76] Li L, Shen T, Li Y-K. A finite element analysis of stress distribution and disk displacement in response to lumbar rotation manipulation in the sitting and side-lying positions. *J Manipulative Physiol Ther*. 2017;40(8):580–586.
- [77] Fujita Y, Duncan NA, Lotz JC. Radial tensile properties of the lumbar annulus fibrosus are site and degeneration dependent. *J Orthop Res*. 1997;15(6):814–819.
- [78] Maitland GD. *Vertebral manipulation*. London: Butterworth-Heinemann; 2013.
- [79] Lundeberg T. Long-term results of vibratory stimulation as a pain relieving measure for chronic pain. *Pain*. 1984;20(1):13–23.
- [80] Lundeberg T, Nordemar R, Ottoson D. Pain alleviation by vibratory stimulation. *Pain*. 1984;20(1):25–44.
- [81] Zusman M, Edwards B, Donaghy A. Investigation of a proposed mechanism for the relief of spinal pain with passive joint movement. *J Manual Med*. 1989;4:58–61.
- [82] Cho BY, Murovic J, Park KW, et al. Lumbar disc rehydration postimplantation of a posterior dynamic stabilization system: case report. *J Neurosurg Spine*. 2010;13(5):576–580.
- [83] Yilmaz A, Senturk S, Sasani M, et al. Disc rehydration after dynamic stabilization: a report of 59 cases. *Asian Spine J*. 2017;11(3):348.
- [84] Kaltenborn F, Evjenth O. *Manual mobilization of the joints: the Kaltenborn method of joint examination and treatment*. Vol. II. The spine 5th ed. Oslo: Norli; 2009.
- [85] Kaltenborn FMKT. *Manual mobilization of the joints*, Vol. 3: traction-manipulation of the extremities and Spine. Oslo: Norli; 2008.
- [86] Murphy DR, Hurwitz EL, Gregory AA, et al. A non-surgical approach to the management of lumbar spinal stenosis: a prospective observational cohort study. *BMC Musculoskel Disord*. 2006;7(1):16.

- [87] Gay RE, Ilharreborde B, Zhao KD, et al. Stress in lumbar intervertebral discs during distraction: a cadaveric study. *Spine J*. 2008;8(6):982–990.
- [88] Sheng B, Yi-Kai L, Wei-dong Z. Effect of simulating lumbar manipulations on lumbar nucleus pulposus pressures. *J Manipulative Physiol Ther*. 2002;25(5):8A–11A.
- [89] Ramos G, Martin W. Effects of vertebral axial decompression on intradiscal pressure. *J Neurosurg*. 1994;81(3):350–353.
- [90] Gudavalli M, Cox J, Baker J. Intervertebral disc pressure changes during the flexion-distraction procedure. Paper presented at: International Society for the Study of the Lumbar Spine Conference, Singapore, 1997.
- [91] Andersson G, Schultz AB, Nachemson A. Intervertebral disc pressures during traction. *Scand J Rehabil Med Suppl*. 1983;9(2):88–91.
- [92] Gay RE, Bronfort G, Evans RL. Distraction manipulation of the lumbar spine: a review of the literature. *J Manipulative Physiol Ther*. 2005;28(4):266–273.
- [93] Johannessen W, Vresilovic EJ, Wright AC, et al. Intervertebral disc mechanics are restored following cyclic loading and unloaded recovery. *Ann Biomed Eng*. 2004;32(1):70–76.
- [94] Bezci SE, Nandy A, O'Connell GD. Effect of hydration on healthy intervertebral disk mechanical stiffness. *J Biomech Eng*. 2015;137(10):10.
- [95] Goodsell M. Short-term effects of lumbar posteroanterior mobilization in individuals with low-back pain. *J Manipulative Physiol Ther*. 2000;23(5):332–342.
- [96] Powers CM, Beneck GJ, Kulig K, et al. Effects of a single session of posterior-to-anterior spinal mobilization and press-up exercise on pain response and lumbar spine extension in people with nonspecific low back pain. *Phys Ther*. 2008;88(4):485–493.
- [97] Beattie PF, Arnot CF, Donley JW, et al. The immediate reduction in low back pain intensity following lumbar joint mobilization and prone press-ups is associated with increased diffusion of water in the L5-S1 intervertebral disc. *J Orthop Sports Phys Ther*. 2010;40(5):256–264.
- [98] Beattie PF, Donley JW, Arnot CF, et al. The change in the diffusion of water in normal and degenerative lumbar intervertebral discs following joint mobilization compared to prone lying. *J Orthop Sports Phys Ther*. 2009;39(1):4–11.
- [99] Beattie PF, Morgan PS, Peters D. Diffusion-weighted magnetic resonance imaging of normal and degenerative lumbar intervertebral discs: a new method to potentially quantify the physiologic effect of physical therapy intervention. *J Orthop Sports Phys Ther*. 2008;38(2):42–49.
- [100] Panjabi MM. The stabilizing system of the spine. Part I. Function, dysfunction, adaptation, and enhancement. *J Spinal Disord*. 1992;5(4):383.
- [101] Porterfield J, DeRosa C. Structural and functional considerations of the lumbopelvic musculature. Mechanical low back pain: perspectives in functional anatomy. Philadelphia, PA: WB Saunders; 1991. p. 47–82.
- [102] Rabin A, Shashua A, Pizem K, et al. The interrater reliability of physical examination tests that may predict the outcome or suggest the need for lumbar stabilization exercises. *J Orthop Sports Phys Ther*. 2013;43(2):83–90.
- [103] Fennell AJ, Jones AP, Hukins DW. Migration of the nucleus pulposus within the intervertebral disc during flexion and extension of the spine. *Spine (Phila PA 1976)*. 1996;21(23):2753–2757.
- [104] Beattie PF, Brooks WM, Rothstein JM, et al. Effect of lordosis on the position of the nucleus pulposus in supine subjects. A study using magnetic resonance imaging. *Spine (Phila PA 1976)*. 1994;19(18):2096–2102.
- [105] Zou J, Yang H, Miyazaki M, et al. Dynamic bulging of intervertebral discs in the degenerative lumbar spine. *Spine*. 2009;34(23):2545–2550.
- [106] Merriam W, Quinnell R, Stockdale H, et al. The effect of postural changes on the inferred pressures within the nucleus pulposus during lumbar discography. *Spine (Phila PA 1976)*. 1984;9(4):405–408.
- [107] Adams MA, May S, Freeman BJ, et al. Effects of backward bending on lumbar intervertebral discs: relevance to physical therapy treatments for low back pain. *Spine (Phila PA 1976)*. 2000;25(4):431–438.
- [108] Schnebel BE, Simmons JW, Chowning J, et al. A digitizing technique for the study of movement of intradiscal dye in response to flexion and extension of the lumbar spine. *Spine (Phila PA 1976)*. 1988;13(3):309–312.
- [109] Lotz JC, Hadi T, Bratton C, et al. Anulus fibrosus tension inhibits degenerative structural changes in lamellar collagen. *Eur Spine J*. 2008;17(9):1149.
- [110] Klausner AS, Gasser JM, Bamidele JO, et al. Assessment of dynamic traction therapy in lumbar disc herniation by clinical and magnetic resonance imaging outcomes. *Int J Eng Res Sci (IJOER)*. 2015;1(8):20–26.
- [111] Cholewicki J, Lee AS, Reeves NP, et al. Trunk muscle response to various protocols of lumbar traction. *Man Ther*. 2009;14(5):562–566.
- [112] Rubinic DM, Koo V, Dudley J, et al. Changes in spinal height after manual axial traction or side lying: a clinical measure of intervertebral disc hydration using stadiometry. *J Manip Physiol Ther*. 2019;42(3):187–194.
- [113] Apfel CC, Cakmakaya OS, Martin W, et al. Restoration of disk height through non-surgical spinal decompression is associated with decreased discogenic low back pain: a retrospective cohort study. *BMC Musculoskelet Disord*. 2010;11(1):155.
- [114] Guehring T, Omlor GW, Lorenz H, et al. Disc distraction shows evidence of regenerative potential in degenerated intervertebral discs as evaluated by protein expression, magnetic resonance imaging, and messenger ribonucleic acid expression analysis. *Spine (Phila PA 1976)*. 2006;31(15):1658–1665.
- [115] Urban JP, Smith S, Fairbank JC. Nutrition of the intervertebral disc. *Spine (Phila PA 1976)*. 2004;29(23):2700–2709.
- [116] Wilke H-J, Wolf S, Claes LE, et al. Stability increase of the lumbar spine with different muscle groups. A biomechanical in vitro study. *Spine (Phila PA 1976)*. 1995;20(2):192–198.
- [117] Ward SR, Kim CW, Eng CM, et al. Architectural analysis and intraoperative measurements demonstrate the unique design of the multifidus muscle for lumbar spine stability. *J Bone Joint Surg Am*. 2009;91(1):176.
- [118] Rosatelli AL, Ravichandiran K, Agur AM. Three-dimensional study of the musculotendinous architecture of lumbar multifidus and its functional implications. *Clin Anat*. 2008;21(6):539–546.
- [119] MacDonald DA, Moseley GL, Hodges PW. The lumbar multifidus: does the evidence support clinical beliefs? *Man Ther*. 2006;11(4):254–263.
- [120] Macintosh JE, Valencia F, Bogduk N, et al. The morphology of the human lumbar multifidus. *Clin Biomech*. 1986;1(4):196–204.

- [121] Freeman MD, Woodham MA, Woodham AW. The role of the lumbar multifidus in chronic low back pain: a review. *PM&R*. 2010;2(2):142–146.
- [122] Hides JA, Richardson CA, Jull GA. Multifidus muscle recovery is not automatic after resolution of acute, first-episode low back pain. *Spine (Phila PA 1976)*. 1996;21(23):2763–2769.
- [123] Hodges PW, James G, Blomster L, et al. Multifidus muscle changes after back injury are characterized by structural remodeling of muscle, adipose and connective tissue, but not muscle atrophy. *Spine (Phila PA 1976)*. 2015;40(14):1057–1071.
- [124] Shahidi B, Parra CL, Berry DB, et al. Contribution of lumbar spine pathology and age to paraspinal muscle size and fatty infiltration. *Spine (Phila PA 1976)*. 2017;42(8):616.
- [125] Shu C, Dart A, Clarke E, et al. Prevention and treatment of intervertebral disc degeneration with bone marrow derived stem (stromal) cells – an in vivo study in sheep. *Osteoarthritis Cartilage*. 2014;22:S28–S29.
- [126] Brown SH, Gregory DE, Carr JA, et al. ISSLS prize winner: adaptations to the multifidus muscle in response to experimentally induced intervertebral disc degeneration. *Spine (Phila PA 1976)*. 2011;36(21):1728–1736.
- [127] Shahidi B, Hubbard JC, Gibbons MC, et al. Lumbar multifidus muscle degenerates in individuals with chronic degenerative lumbar spine pathology. *J Orthop Res*. 2017;35(12):2700–2706.
- [128] Hodges P, Coppieters M, MacDonald D, et al. New insight into motor adaptation to pain revealed by a combination of modelling and empirical approaches. *Eur J Pain*. 2013;17(8):1138–1146.
- [129] MacDonald D, Moseley GL, Hodges PW. Why do some patients keep hurting their back? Evidence of ongoing back muscle dysfunction during remission from recurrent back pain. *Pain*. 2009;142(3):183–188.
- [130] van Dieën JH, Selen LP, Cholewicki J. Trunk muscle activation in low-back pain patients, an analysis of the literature. *J Electromyogr Kinesiol*. 2003;13(4):333–351.
- [131] Mok NW, Brauer SG, Hodges PW. Changes in lumbar movement in people with low back pain are related to compromised balance. *Spine (Phila PA 1976)*. 2011;36(1):E45–E52.
- [132] Goldspink G, Scutt A, Loughna PT, et al. Gene expression in skeletal muscle in response to stretch and force generation. *Am J Physiol Regul Integr Comp Physiol*. 1992;262(3):R356–R363.
- [133] Loughna P, Izumo S, Goldspink G, et al. Disuse and passive stretch cause rapid alterations in expression of developmental and adult contractile protein genes in skeletal muscle. *Development*. 1990;109(1):217–223.
- [134] Burkholder TJ. Mechanotransduction in skeletal muscle. *Front Biosci*. 2007;12(1):174.
- [135] Khan KM, Scott A. Mechanotherapy: how physical therapists' prescription of exercise promotes tissue repair. *Br J Sports Med*. 2009;43(4):247–252.
- [136] Goldspink G. Changes in muscle mass and phenotype and the expression of autocrine and systemic growth factors by muscle in response to stretch and overload. *J Anat*. 1999;194(3):323–334.
- [137] Joshi SK, Liu X, Samagh SP, et al. mTOR regulates fatty infiltration through SREBP-1 and PPAR γ after a combined massive rotator cuff tear and suprascapular nerve injury in rats. *J Orthop Res*. 2013;31(5):724–730.
- [138] Danneels L, Vanderstraeten G, Cambier D, et al. Effects of three different training modalities on the cross sectional area of the lumbar multifidus muscle in patients with chronic low back pain. *Br J Sports Med*. 2001;35(3):186–191.
- [139] O'Sullivan PB, Phyt GDM, Twomey LT, et al. Evaluation of specific stabilizing exercise in the treatment of chronic low back pain with radiologic diagnosis of spondylolysis or spondylolisthesis. *Spine (Phila PA 1976)*. 1997;22(24):2959–2967.
- [140] Lederman E. *Fundamentals of manual therapy: physiology, neurology, and psychology*. London: Churchill Livingstone; 1997.
- [141] Wallwork TL, Stanton WR, Freke M, et al. The effect of chronic low back pain on size and contraction of the lumbar multifidus muscle. *Man Ther*. 2009;14(5):496–500.
- [142] Javadian Y, Akbari M, Talebi G, et al. Influence of core stability exercise on lumbar vertebral instability in patients presented with chronic low back pain: a randomized clinical trial. *Caspian J Intern Med*. 2015;6(2):98.
- [143] Sterling M, Jull G, Wright A. Cervical mobilisation: concurrent effects on pain, sympathetic nervous system activity and motor activity. *Man Ther*. 2001;6(2):72–81.
- [144] Mehyar F, Santos M, Wilson SE, et al. Immediate effect of lumbar mobilization on activity of erector spinae and lumbar multifidus muscles. *J Chiropr Med*. 2017;16(4):271–278.
- [145] Fritz JM, Koppenhaver SL, Kawchuk GN, et al. Preliminary investigation of the mechanisms underlying the effects of manipulation: exploration of a multi-variate model including spinal stiffness, multifidus recruitment, and clinical findings. *Spine (Phila PA 1976)*. 2011;36(21):1772.
- [146] Haldorsen EMH. The right treatment to the right patient at the right time. *Occup Environ Med*. 2003;60(4):235–236.